

Enhancement of tongue carcinogenesis in Hras128 transgenic rats treated with 4-nitroquinoline 1-oxide

KUNIKO NAOI¹, NAO SUNAGAWA², ICHIRO YOSHIDA¹, TAKAMITSU MORIOKA²,
MAKOTO NAKASHIMA¹, MASASHI ISHIHARA^{1,3}, KATSUMI FUKAMACHI⁴,
YOSHINORI ITOH³, HIROYUKI TSUDA⁴, NAOKI YOSHIMI² and MASUMI SUZUI¹

¹Department of Medical Therapeutics and Molecular Therapeutics, Gifu Pharmaceutical University, 5-6-1 Mitahora-higashi, Gifu 502-8585; ²Tumor Pathology Division, University of the Ryukyus Faculty of Medicine, 207 Uehara, Nishihara-cho, Okinawa 903-0215; ³Department of Pharmacy, Gifu University Hospital, 1-1 Yanagido, Gifu 501-1194; ⁴Department of Molecular Toxicology, Graduate School of Medical Sciences, Nagoya City University, 1 Kawasumi, Mizuho-cho, Mizuho-ku, Nagoya 467-8601, Japan

Received September 3, 2009; Accepted October 29, 2009

DOI: 10.3892/or_00000641

Abstract. Transgenic rats carrying human c-Ha-*ras* proto-oncogene (Hras128 rats) have been shown to be highly susceptible to induction of tumors. We have found an early induction of tongue tumors in Hras128 rats treated with 4-nitroquinoline 1-oxide (4NQO). 4NQO was administered to the Hras128 and wild-type Sprague-Dawley (SD) rats for 4 and 8 weeks, respectively. The experiment was terminated at 14 (Hras128 rats) and 28 (SD rats) weeks. Either during or after treatment with 4NQO, dysplastic hyperplasia, papilloma and squamous cell carcinoma were found on the tongue of both Hras128 and wild-type rats, with a higher incidence and multiplicity in Hras128 rats. Treatment of the Hras128 rats with 4NQO significantly increased cell proliferation in the tumor compared to the control rats. In the tongue tumors of the Hras128 rats, there was a significant increase in the mRNA expression levels of cyclin D1 and COX2. To examine whether this experimental system is useful for screening of the candidate agents for cancer preventive effect, nimesulide, a selective COX2 inhibitor, was tested in the present model. Nimesulide significantly decreased total multiplicity of tongue lesions compared to the control rats. Treatment of Hras128 rats with nimesulide caused a significant decrease in the levels of mRNA expression of cyclin D1 and COX2 in the tumor. Therefore, the current 4NQO-induced Hras128 rat tongue carcinogenesis model provides a simple and rapid system for investigating carcino-

genesis process and evaluating the effect of possible cancer preventive agents for human tongue cancer.

Introduction

Oral cancer is a relatively common malignancy ranking 11th in frequency on a worldwide basis, and more than 390,000 new cases are being diagnosed annually (1,2). Human oral cancer is related to cigarette smoking and chewing or smokeless tobacco (3). This disease has a multifocal character often referred to as a field cancerization (4). This malignancy is most common in developing countries of Asia and South America (5), and incidence and mortality rate of this disease are rising in developed countries, especially in young males (6-8). This aggressive epithelial malignancy is associated with severe morbidity and poor survival despite recent advances in treatment (7).

Rat model using 4-nitroquinoline 1-oxide (4NQO) has been widely used for investigating carcinogenesis of oral cancer and evaluating the modulatory effects of possible chemopreventive agents (9,10). The 4NQO-induced oral cancer is derived from papilloma through hyperplastic epithelium and dysplasia (11), and this multistage process mimics the development of these malignancies in human (11,12). Recent reports by Tsuda and his colleagues demonstrate that transgenic rat carrying human c-Ha-*ras* proto-oncogene, termed Hras128 rat [Jcl/SD-TgN(HrasGen)128Ncc], is highly susceptible to tumor induction in various organ sites including mammary gland, esophagus, skin, urinary bladder and tongue (13-15).

In the present study, we developed a novel tongue carcinogenesis Hras128 rat model by using 4NQO to cause a rapid induction of tongue tumors within as short a period as 14 experimental weeks. Using this experimental system, we also confirmed that nimesulide, a selective COX2 inhibitor, which has been demonstrated to prevent rat tongue carcinogenesis (16), prevents the occurrence of tongue tumors induced with 4NQO.

Correspondence to: Dr Masumi Suzui, Department of Medical Therapeutics and Molecular Therapeutics, Gifu Pharmaceutical University, 5-6-1 Mitahora-higashi, Gifu 502-8585, Japan
E-mail: suzui@gifu-pu.ac.jp

Key words: tongue carcinogenesis, *ras*, transgenic rat, 4-nitroquinoline 1-oxide

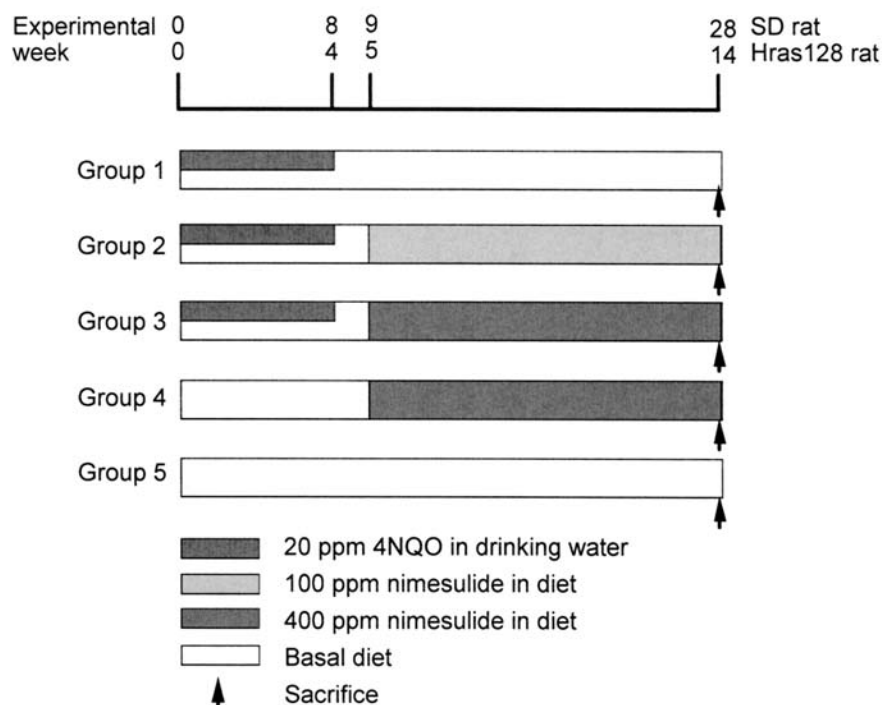


Figure 1. Experimental protocol. As indicated, the experimental period of the Hras128 and wild-type SD rat lasted 14 and 28 weeks, respectively.

Materials and methods

Animals. A total of 80 male Hras128 rats [Jcl/SD-TgN (HrasGen)128Ncc] and wild-type Sprague-Dawley (SD) rats bred by CLEA (CLEA Japan, Inc., Tokyo, Japan) at 6 weeks old were maintained in plastic cages in a conditioned room at $23\pm 2^{\circ}\text{C}$, $50\pm 10\%$ humidity and 12-h light/dark cycle lighting. The animals were allowed free access to powdered basal diet CE-2 (CLEA Japan) and tap water. The animals were also maintained in the Animal Facility of University of the Ryukyus, Faculty of Medicine, and the experiments were conducted according to the Institutional Animal Care Guidelines of University of the Ryukyus.

Treatment. After one week of acclimatization, rats were randomly assigned to the experimental groups (Fig. 1). Hras128 and SD rats in groups 1-3 (10 rats each) were given tap water containing 20 ppm 4NQO (CAS no. 56-57-5, Wako Pure Chemical, Osaka, Japan; 98% pure) for 4 and 8 weeks, respectively. One week after 4NQO treatment, rats in groups 2 and 3 received 100 and 400 ppm nimesulide (CAS no. 51803-78-2, Nacalai Tesque, Inc., Kyoto, Japan) in basal diet until the end of the experiment, and rats in group 1 received no further treatment and fed the basal diet. Rats in group 4 received the 400 ppm nimesulide diet without 4NQO treatment. Rats in group 5 were fed the basal diet alone and served as untreated controls. Careful observation of tongue lesions was done on a weekly basis until the end of the experiment. Animals were weighed weekly and consumption of the experimental diets was also recorded. Tongue lesions including dysplastic hyperplasia (DH), papilloma (PAP) and squamous cell carcinoma (SCC) were noted grossly for their location, number, and size, and tumor incidence and multiplicity were

analyzed. At 14 and 28 weeks after the start of the experiment, Hras128 and SD rats were euthanized with CO_2 anesthesia, and then complete autopsies were performed with these animals. The identified tumors were carefully removed and cut into two segments. One segment of the tumor was immediately frozen in liquid nitrogen for reverse transcription-PCR (RT-PCR) analysis; the second segment was fixed in 10% buffered formalin and then processed for histopathological (hematoxylin and eosin staining) and immunohistochemical analyses. Oral lesions including dysplasia and neoplasia were diagnosed according to the criteria described elsewhere (17,18).

Immunohistochemical staining and measurement of PCNA positive index. These assays were performed using an established method as previously described by us (19). In brief, 4- μm thick paraffin sections were prepared to include the tongue tumor or adjacent normal mucosa. These sections were treated in 3% H_2O_2 for 20 min to block the endogenous peroxidase activity and then incubated with a primary antibody of proliferating cell nuclear antigen (PCNA) (1:50 dilution) (Dako Co., Ltd., Kyoto, Japan) at room temperature for 60 min. Sections were then stained using a Simple Stain kit (Nichirei, Tokyo, Japan) according to the manufacturer's instructions. PCNA was measured in cells consisting of the tongue tumor or normal mucosa. The PCNA positive index was determined by calculating the ratio of PCNA-positive nuclei/total number of nuclei counted as described by us (19). More than 300 cells were counted in each lesion.

Reverse transcription-PCR (RT-PCR) analysis. These assays were performed by established procedures (20). Snap-frozen

Table I. Body, liver, kidney and relative liver weights in Hras128 rats.

Group	Treatment	No. of rats	Body weight (g)	Liver weight (g)	Kidney weight (g)	Relative liver weight (g/100 gr body weight)
1	4NQO	10	597±30 ^{a,b}	24.6±2.9 ^b	4.7±0.4	4.1±0.3 ^b
2	4NQO→100 ppm nimesulide	10	577±24	22.4±3.1	4.6±0.4	3.8±0.4
3	4NQO→400 ppm nimesulide	10	531±42 ^b	24.8±2.7	4.6±0.5	4.6±0.4 ^b
4	400 ppm nimesulide	5	588±20	26.0±2.8	4.8±0.5	4.4±0.4
5	None	5	625±60 ^b	28.0±4.8 ^b	5.2±0.1	4.4±0.6

^aMean ± SD. ^bStatistically significant.

Table II. Body, liver, kidney and relative liver weights in Sprague-Dawley rats.

Group	Treatment	No. of rats	Body weight (g)	Liver weight (g)	Kidney weight (g)	Relative liver weight (g/100 gr body weight)
1	4NQO	8	523±100 ^{a,b}	19.7±5.9	3.7±0.5 ^b	3.7±0.8
2	4NQO→100 ppm nimesulide	10	520±77 ^b	20.6±4.5	3.9±0.6	3.9±0.6 ^b
3	4NQO→400 ppm nimesulide	10	538±29 ^b	17.5±3.5 ^b	3.6±0.4	3.2±0.5 ^b
4	400 ppm nimesulide	5	662±96 ^b	24.4±7.1 ^b	5.0±0.8 ^b	3.6±0.8
5	None	5	558±68	18.1±2.9	3.4±0.3	3.2±0.5 ^b

^aMean ± SD. ^bStatistically significant.

histopathologically verified tongue tumors were randomly chosen and total RNA was extracted for RT-PCR assays. Total RNA was isolated from frozen tissues using a TRIzol reagent (Invitrogen Life Technologies, Inc., Rockville, MD) as recommended by the manufacturer. cDNA was amplified from total RNA (100 ng) using a SuperScript III One-Step RT-PCR System (Invitrogen Life Technologies). PCR was conducted for 35 or 38 cycles in a Takara PCR Thermal Cycler SP TP-400 (Takara Bio, Inc., Tokyo, Japan). The primers used for amplification were as follows: cyclin D1-specific primer set, CD-1F (5'-CTG GCC ATG AAC TAC CTG GA-3') and CD-1R (5'-GTC ACA CTT GAT GAC TCT GG-3'); p53-specific primer set, P-2F (5'-CAG CGA CAG GGT CAC CTA AT-3') and P-3R (5'-GTG GAT AGT GGT ATA GTC GG-3'); p21^{CIP1}-specific primer set, C-3F (5'-CCT TAG CCT TCA TTC AGT GT-3') and C-4R (5'-GCC AGG ATC AGA AAC ACA GC-3'); p27^{KIP1}-specific primer set, K-2F (5'-CCG CCT GCA GAA ACC TCT TC-3') and K-2R (5'-TGG ACA CTG CTC CGC TAA CC-3'); cyclooxygenase-2 (COX2)-specific primer set, PT-4F (5'-TGG GCC ATG GAG TGG ACT TA-3') and PT-4R (5'-ATG AGC CTG CTG GTT TGG AA-3'). β -actin-specific PCR products for the same RNA samples were simultaneously amplified and served as internal controls. Primers BA-F2 (5'-GGG TAT GGG TCA GAA

GGA CT-3') and BA-R2 (5'-TGT AGC CAC GCT CGG TCA GG-3') were used for amplification of β -actin. Each amplification cycle consisted of 0.5 min at 94°C for denaturing, 0.5 min at 55°C for primer annealing and 1 min at 72°C for extension. PCR products were analyzed by agarose gel electrophoresis and stained with ethidium bromide. The results were confirmed by repeating experiments.

Statistical analysis. Tumor incidence and multiplicity were compared between the Hras128 and SD rats, or between animals treated with nimesulide and those not treated with nimesulide. Tumor incidence was analyzed by χ^2 or Fisher's exact probability test, and tumor multiplicity was analyzed by Student's or Welch's t-test. Significance was established at $P < 0.05$.

Results

General observation. A total of 78 Hras128 and SD rats survived at the end of the experiment. Two SD rats in group 1 died from unidentified cause. No macroscopic metastases were observed in any of 78 rats. Body, liver, kidney and relative liver weights are shown in Tables I and II. In Table I, the body weight of group 3 was significantly lower than that

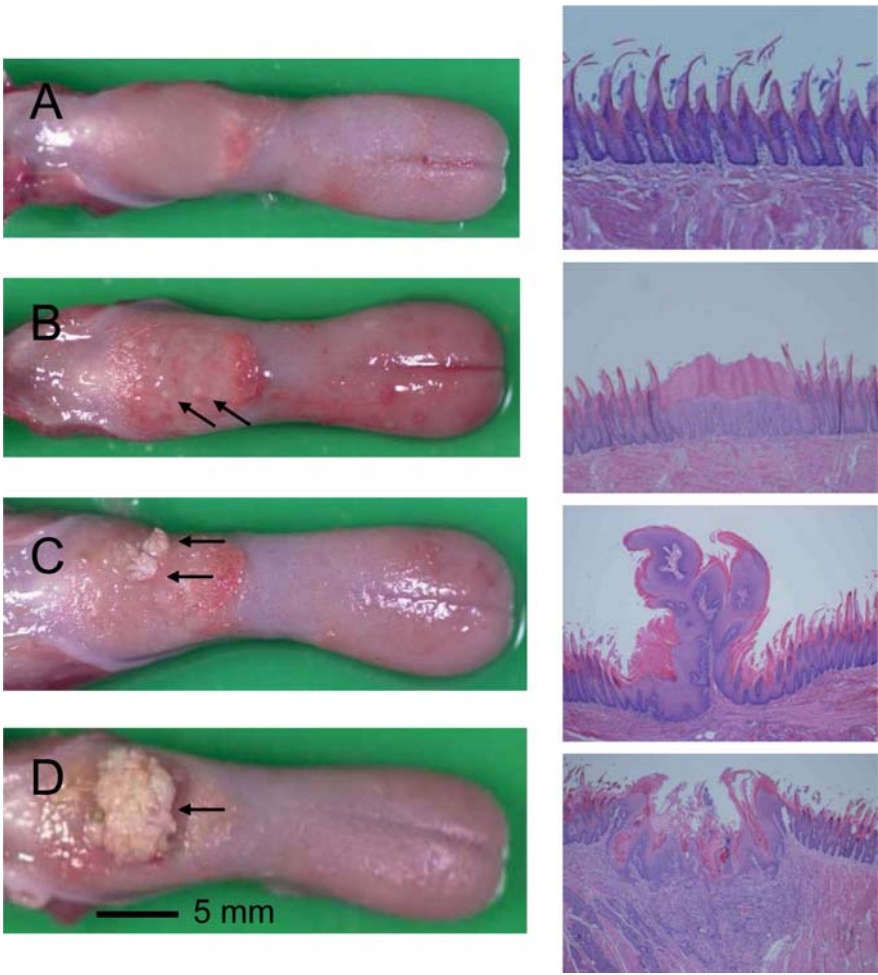


Figure 2. Macroscopic (left panels) and histological (right panels) appearance on the induced tongue lesions indicated by arrows. These lesions were induced with 4NQO in Hras128 rats. (A) Normal mucosa (N); (B) dysplastic hyperplasia (DH); (C) papilloma (PAP); (D) squamous cell carcinoma (SCC) (arrow). DH displayed thickened epithelium with prominent surface keratinization, loss of polarity in epithelial cells, nuclear pleomorphism, dyskeratosis and increased or abnormal mitosis. PAP and SCC exhibited non-invasive growth of neoplastic cells and invasive growth into subepithelial and muscular tissues, respectively.

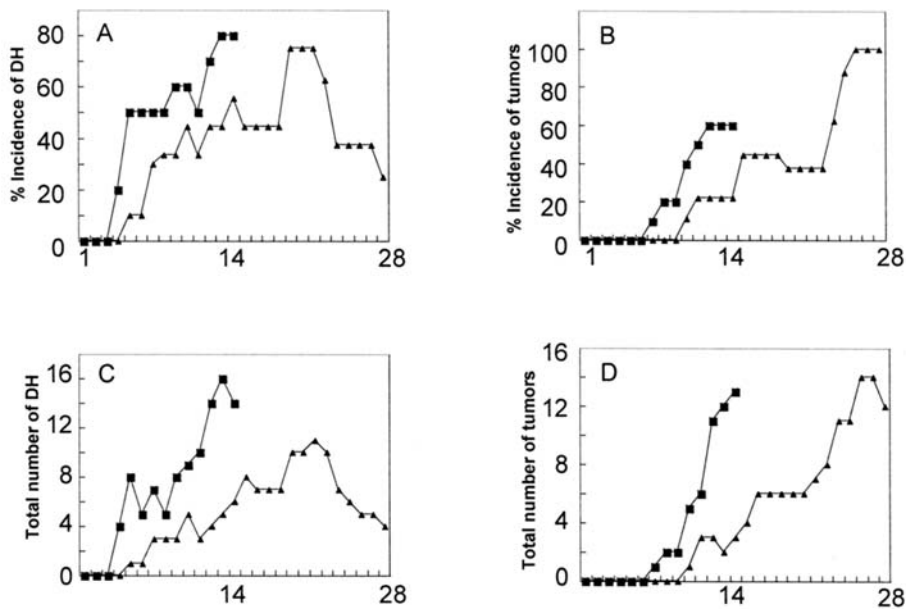


Figure 3. Occurrence of tongue lesions in Hras128 (closed square) and SD (closed triangle) rats. As indicated, left 2 panels indicate (%) incidence (A) and number (C) of dysplastic hyperplasia (DH). Note a marked increase in incidence and number of DH in Hras128 rats. This increase persisted until the end of the experiment (at experimental-week 14). Right 2 panels indicate (%) incidence (B) and number (D) of tumor. X-axis indicates the experimental week. Note that the incidence and number of tongue tumors (PAP and SCC) in the Hras128 rat are greater than that of the SD rat.

Table III. Incidence and multiplicity of the tongue lesions.

A. Hras128 rat

Group	Treatment	No. of rats	Incidence			Multiplicity		
			Total	DH	PAP+SCC	Total	DH	PAP+SCC
1	4NQO	10	8	8	6	3.4±2.1 ^a	1.8±1.0	2.2±0.2
2	4NQO→100 ppm nimesulide	10	9	7	4	2.0±1.0	1.7±1.1	1.2±0.5
3	4NQO→400 ppm nimesulide	10	8	7	2 ^b	1.6±0.7 ^c	1.4±0.8	1.0±0.1
4	400 ppm nimesulide	5	0	0	0	0	0	0
5	None	5	0	0	0	0	0	0

^aMean ± SD. ^bSignificantly different from group 1 by χ^2 test (P<0.05). ^cSignificantly different from group 1 by Student's t-test (P<0.05). DH, dysplastic hyperplasia; PAP, papilloma; SCC, squamous cell carcinoma.

B. SD rat

Group	Treatment	No. of rats	Incidence			Multiplicity		
			Total	DH	PAP+SCC	Total	DH	PAP+SCC
1	4NQO	8	8	3	8	1.8±0.8 ^a	2.0±1.4	1.5±0.8
2	4NQO→100 ppm nimesulide	10	10	2	8	1.6±0.7	1.3±0.6	1.5±0.8
3	4NQO→400 ppm nimesulide	10	10	2	8	1.3±0.7 ^b	1.0±0.1	1.2±0.4
4	400 ppm nimesulide	5	0	0	0	0	0	0
5	None	5	0	0	0	0	0	0

^aMean ± SD. ^bSignificantly different from group 1 by Student's t-test (P<0.05). DH, dysplastic hyperplasia; PAP, papilloma; SCC, squamous cell carcinoma.

of groups 1 (P<0.001) and 5 (P<0.01). Liver and relative liver weights of group 1 were significantly lower than that of groups 5 (P<0.01) and 3 (P<0.01), respectively. In Table II, the body weight of groups 1-3 was significantly lower than that of group 4 (P<0.05). Kidney and liver weights of group 1 and 3, respectively, were significantly lower than that of group 4 (P<0.05). Relative liver weight of group 2 was higher than that of groups 3 and 5 (P<0.05). These data indicate a toxic effect of 4NQO on the carcinogen-treated animals and that nimesulide may affect the weight of the body and the organs examined.

Occurrence of tongue lesions. On the time course study, an early induction of grossly visible tongue lesions including DH and tumor was found. These lesions were histopathologically DH, PAP and SCC (Fig. 2). After 3 weeks of 4NQO treatment, the incidence and number of DH in Hras128 rats markedly increased, and this increase persisted until the end of the experiment (at experimental-week 14) (Fig. 3A and C). In the DH lesion of Hras128 rats, treatment with 4NQO resulted in a 1.4- and 2.3-fold increase in incidence and

number, respectively, when compared to the SD rats. At the experimental-week 14, the incidence and number of tongue tumors in the Hras128 rat were greater than that of the SD rat (Fig. 3B and D). Also, treatment of Hras128 rats with 4NQO resulted in a 2.7- and 4.3-fold increase in tumor incidence and number, respectively, when compared to the SD rats. At the end of the experiment, there was a significant increase in tumor multiplicity of the Hras128 rat (2.2±0.2) in comparison to the SD rat (1.5±0.8) (P<0.05). No visible esophageal tumors were found in any group of the Hras128 and SD rats.

Incidence and multiplicity of the tongue lesions. Treatment of Hras128 rats with 400 ppm nimesulide caused a significant and dose-dependent decrease in tumor incidence and total tumor multiplicity compared to group 1 (P<0.05, Table IIIA). In SD rats, the total tumor multiplicity was significantly decreased at 400 ppm nimesulide treatment (P<0.05, Table IIIB). In treatment of Hras128 and SD rats with nimesulide, the incidence and multiplicity were decreased in value but these changes were not statistically significant (Table III).

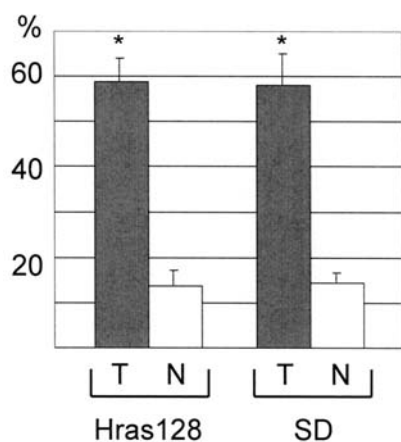


Figure 4. Proliferating cell nuclear antigen (PCNA) positive index in the tumor (T) and normal (N) tongue mucosa. Asterisks indicate significant difference in PCNA positive index between tumor and normal mucosa (Student's t-test, $P < 0.05$). The difference was seen in both Hras128 and SD rats.

Positive index. To examine the effect of 4NQO in cell proliferation, we measured PCNA positive index in the tumor of group 1 and normal mucosa of group 5 (Fig. 4). In Hras128 rats, PCNA positive index was 58.8 ± 4.9 (tumor) and 13.8 ± 3.0 (normal mucosa). In SD rats, PCNA positive index was 58.1 ± 6.6 (tumor) and 14.3 ± 2.2 (normal mucosa). As shown in Fig. 4, treatment of Hras128 and SD rats with 4NQO caused a significant increase in PCNA positive index ($P < 0.05$). These results indicate that treatment of rats with 4NQO increased cell proliferation in the tumor.

mRNA expression levels in the tumor of Hras128 rats. Because we found that at sacrifice the Hras128 rat developed greater number of tongue tumors than the SD rat and that 4NQO treatment enhanced cell proliferation in the tumor, we analyzed the levels of expression of cyclin D1, p21^{CIP1}, p27^{KIP1}, p53, COX2, using quantitative reverse transcription PCR (RT-PCR) assays. In tumor samples of the Hras128 rat, there was a marked (6.5- to 7.5-fold) and significant increase in the cellular levels of cyclin D1 and COX2 mRNA compared to the adjacent normal mucosa samples (Fig. 5). There was also a slight (1.7- to 2.3-fold) increase in those of p53 and p21^{CIP1} mRNA (Fig. 5). We then examined whether nimesulide affects the levels of expression of these molecules in the tumors of Hras128 rats. Nimesulide caused a marked decrease in the cellular level of COX2, and also caused a slight decrease in that of cyclin D1 mRNA. Nimesulide treatment at high dose (400 ppm) inhibited the expression of COX2 mRNA to almost zero level. Nimesulide also caused a slight decrease in the cellular level of cyclin D1 mRNA.

Discussion

Treatment of Hras128 rats with 4NQO caused an early induction (up to six experimental weeks) of DH and tumor in the tongue, when compared to the wild-type SD rat (Table III and Fig. 3). These results clearly show that Hras128 rats are more sensitive to 4NQO induced tongue carcinogenesis than SD rats. This susceptibility to a carcinogen is in accordance

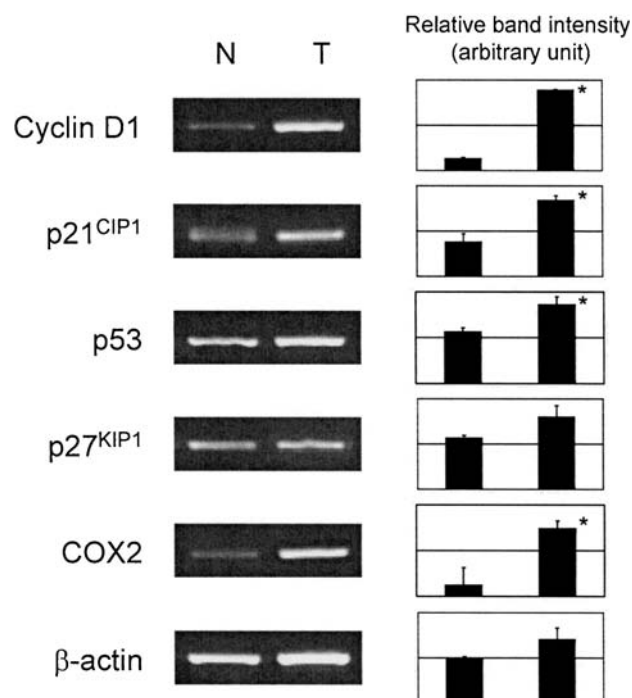


Figure 5. Representative results of RT-PCR assays. Densitometric analysis (right panel). Asterisks indicate significant difference between tumor (T) and adjacent normal mucosa (N) ($P < 0.05$).

with previous experiments demonstrating that Hras128 rats are more sensitive to a 7,12-dimethylbenz[*a*]anthracene (DMBA) or 4NQO in the mammary or tongue tumors than were wild-type SD rats (11,21). In addition, Miyamoto *et al* demonstrated that the rasH2 mouse carcinogenesis model is highly susceptible to 4NQO induced tongue and esophageal tumors (12). In the present study, after three weeks of 4NQO treatment DH of the tongue epithelium in Hras128 rats markedly increased with respect to incidence and number, when compared with this lesion in SD rats (Fig. 3). The incidence and number of tongue tumors (PAP and SCC) also markedly increased after 6 weeks of 4NQO exposure, and this increase persisted until the end of the experiment (at experimental-week 14), when compared with these lesions in SD rats. In conventional 4NQO initiated carcinogenesis models, oral tumors are induced during 22-32 experimental weeks (11,22). In the present model, tongue tumors can be induced in only a short period of 14 experimental weeks. We therefore conclude that 4NQO-induced tongue carcinogenesis was extensively enhanced in the Hras128 rat.

Human oral cancer is a focal disorder (3), and experimental studies have indicated that there is a multistage process in the development of the oral lesions, in which dysplasias process to SCC through PAP (11,12). The results obtained in the present study showing that Hras128 and SD rats developed DH and tumors in a time-dependent manner (Fig. 3) is consistent with the established facts on human oral cancer. In addition, because of the ease of examining the lesions, the oral cavity is an excellent target organ for experimental studies. Therefore, the DH lesion may provide a useful biomarker for clarifying detailed carcinogenesis process and also provide clues to causative agents in human oral cancer.

The Ha-*ras* codon 12 and 61 mutations in human oral SCC occur at a frequency of approximately 35% (22). Previously we have reported that mutations in the *ras* family genes are 17% in 4NQO induced rat tongue tumors (23). The current Hras128 rats carry copies of the human c-Ha-*ras* transgene in their genome (15). The alkylating agent 4NQO is a powerful carcinogen in several organs (10), and it causes Ha-*ras* gene mutations by forming DNA adducts especially to guanine (N2, N7 and N8 positions) or adenine (N1 and N6 positions) (24-26). In a parallel study using Hras128 rats (unpublished data), no mutations were found in either endogenous rat c-Ha-*ras* gene or exogenous human c-Ha-*ras* gene in any tissue of DH, PAP SCC and normal mucosa, suggesting that in the present model the oral dysplasias progress to SCC via a mechanism, not involving mutational activation of the *ras* gene. In previous experiments, the transduced exogenous human c-Ha-*ras* gene was somatically mutated in the tumors of *N*-methyl-*N*-nitrosourea induced mammary carcinogenesis and *N*-butyl-*N*-(4-hydroxybutyl)nitrosamine induced urinary bladder carcinogenesis models (13,15). In these studies, however, no mutation was found in the endogenous gene. Similar results were also seen in a human c-Ha-*ras* transgenic mouse model (12). Therefore, it is likely that mutation in the transgene itself is not necessarily crucial for malignant progression and that these unique aspects in mutation status may reflect the different susceptibilities of different organs to specific carcinogens or the specificity of gene-carcinogen interactions. However, it remains to be determined whether the *ras* protein accumulates in the cytoplasm and nucleus of these tumors.

Overexpression of cyclin D1 has been found in both human and rat oral tumors (27,28). Overexpression of COX2 has been found in human oral cancer and DMBA induced hamster cheek pouch tumor (29,30). In the present study, we found that in tumor samples of Hras128 rats treatment of 4NQO caused a marked increase in the levels of mRNA expression of cyclin D1 and COX2, when compared to the adjacent normal mucosa (Fig. 5). We also found that treatment of 4NQO resulted in a significant increase in PCNA positive index in the tumor of Hras128 rats, when compared to the normal mucosa (Fig. 4). These analyses were performed in samples obtained at 14 weeks of the experiment. Thus, these results suggest that enhanced cell proliferation cooperates with the up-regulation of cyclin D1 and COX2 to cause a rapid induction of tongue tumors. We also found that mRNA expression levels of p53 and p21^{CIP1} were marginally increased in the tumor of 4NQO-treated Hras128 rats (Fig. 5). This may be consistent with the study by Seo *et al* demonstrating that up-regulation of p53 and p21^{CIP1} is a possible mechanism of nucleotide excision repair in response to 4NQO induced DNA damage (31).

The 4NQO-induced Hras128 rat oral carcinogenesis model may provide a system for evaluation of the mechanisms of multistage oral carcinogenesis and detection of causative agents in human oral cancer. Using this system, we also examined whether the model can be used to identify possible cancer preventive agents. A selective COX2 inhibitor, nimesulide (4-nitro-2-phenoxyethanesulphonanilide) was tested for its modifying effects on 4NQO-induced tongue carcinogenesis. We found that treatment of Hras128 rats with

nimesulide caused a significant and dose-dependent decrease in tumor incidence and multiplicity compared to the control (Table IIIA). In Hras128 rats, treatment of nimesulide markedly decreased the level of expression of COX2 mRNA in the tumor compared to the adjacent normal mucosa. Therefore, the present model may also have some relevance and application to identify cancer preventive agents for human oral cancer. In summary, 4NQO rapidly causes dysplasia in oral squamous epithelia, which leads to PAP and SCC, as it does in human oral lesions. We consider the present Hras128 rat model a simple and rapid system that can be used for assessment of oral carcinogenesis and cancer prevention.

Acknowledgements

This study was supported by a Grant-in-Aid from the Ministry of Health, Labour, and Welfare of Japan, and a Grant-in-Aid from the Ministry of Education, Culture, Sports, Science and Technology of Japan.

References

1. Parkin DM, Bray F, Ferlay J and Pisani P: Global cancer statistics, 2002. *CA Cancer J Clin* 55: 74-108, 2005.
2. Stewart BW and Kleihues P: World Cancer Report, WHO Press, Lyon, 2003.
3. Smith CJ: Global epidemiology and aetiology of oral cancer. *Int Dent J* 23: 82-93, 1973.
4. Slaughter DP, Southwick HW and Smejkal W: Field cancerization in oral stratified squamous epithelium; clinical implications of multicentric origin. *Cancer* 6: 963-968, 1953.
5. Patel V, Leethanakul C and Gutkind JS: New approaches to the understanding of the molecular basis of oral cancer. *Crit Rev Oral Biol Med* 12: 55-63, 2001.
6. Davis S and Severson RK: Increasing incidence of cancer of the tongue in the United States among young adults. *Lancet* 2: 910-911, 1987.
7. Greenlee RT, Hill-Harmon MB, Murray T and Thun M: Cancer statistics, 2001. *CA Cancer J Clin* 51: 15-36, 2001.
8. Mackenzie J, Ah-See K, Thakker N, Sloan P, Maran AG, Birch J and Macfarlane GJ: Increasing incidence of oral cancer amongst young persons: what is the aetiology? *Oral Oncol* 36: 387-389, 2000.
9. Tanaka T, Kohno H, Sakata K, Yamada Y, Hirose Y, Sugie S and Mori H: Modifying effects of dietary capsaicin and rotenone on 4-nitroquinoline 1-oxide-induced rat tongue carcinogenesis. *Carcinogenesis* 23: 1361-1367, 2002.
10. Nakahara W, Fukuoka F and Sugimura T: Carcinogenic action of 4-nitroquinoline-N-oxide. *Gan* 48: 129-137, 1957.
11. Suzuki R, Kohno H, Suzui M, Yoshimi N, Tsuda H, Wakabayashi K and Tanaka T: An animal model for the rapid induction of tongue neoplasms in human c-Ha-*ras* proto-oncogene transgenic rats by 4-nitroquinoline 1-oxide: its potential use for preclinical chemoprevention studies. *Carcinogenesis* 27: 619-630, 2006.
12. Miyamoto S, Yasui Y, Kim M, Sugie S, Murakami A, Ishigamori-Suzuki R and Tanaka T: A novel rasH2 mouse carcinogenesis model that is highly susceptible to 4-NQO-induced tongue and esophageal carcinogenesis is useful for preclinical chemoprevention studies. *Carcinogenesis* 29: 418-426, 2008.
13. Asamoto M, Ochiya T, Toriyama-Baba H, Ota T, Sekiya T, Terada M and Tsuda H: Transgenic rats carrying human c-Ha-*ras* proto-oncogenes are highly susceptible to N-methyl-N-nitrosourea mammary carcinogenesis. *Carcinogenesis* 21: 243-249, 2000.
14. Asamoto M, Toriyama-Baba H, Ohnishi T, Naito A, Ota T, Ando A, Ochiya T and Tsuda H: Transgenic rats carrying human c-Ha-*ras* proto-oncogene are highly susceptible to N-nitrosomethylbenzylamine induction of esophageal tumorigenesis. *Jpn J Cancer Res* 93: 744-751, 2002.
15. Ota T, Asamoto M, Toriyama-Baba H, Yamamoto F, Matsuo Y, Ochiya T, Sekiya T, Terada M, Akaza H and Tsuda H: Transgenic rats carrying copies of the human c-Ha-*ras* proto-oncogene exhibit enhanced susceptibility to N-butyl-N-(4-hydroxybutyl)nitrosamine bladder carcinogenesis. *Carcinogenesis* 21: 1391-1396, 2000.

16. Yoshida K, Tanaka T, Kohno H, Sakata K, Kawamori T, Mori H and Wakabayashi K: A COX-2 inhibitor, nimesulide, inhibits chemically-induced rat tongue carcinogenesis through suppression of cell proliferation activity and COX-2 and iNOS expression. *Histol Histopathol* 18: 39-48, 2003.
17. Banoczy J and Csiba A: Occurrence of epithelial dysplasia in oral leukoplakia. Analysis and follow-up study of 12 cases. *Oral Surg Oral Med Oral Pathol* 42: 766-774, 1976.
18. Kramer IR, Lucas RB, Pindborg JJ and Sobin LH: Definition of leukoplakia and related lesions: an aid to studies on oral precancer. *Oral Surg Oral Med Oral Pathol* 46: 518-539, 1978.
19. Suzui M, Inamine M, Kaneshiro T, Morioka T, Yoshimi N, Suzuki R, Kohno H and Tanaka T: Indole-3-carbinol inhibits the growth of human colon carcinoma cells but enhances the tumor multiplicity and volume of azoxymethane-induced rat colon carcinogenesis. *Int J Oncol* 27: 1391-1399, 2005.
20. Suzui M, Sunagawa N, Chiba I, Moriwaki H and Yoshimi N: Acyclic retinoid, a novel synthetic retinoid, induces growth inhibition, apoptosis, and changes in mRNA expression of cell cycle- and differentiation-related molecules in human colon carcinoma cells. *Int J Oncol* 28: 1193-1199, 2006.
21. Park CB, Fukamachi K, Takasuka N, Han BS, Kim CK, Hamaguchi T, Fujita K, Ueda S and Tsuda H: Rapid induction of skin and mammary tumors in human c-Ha-ras proto-oncogene transgenic rats by treatment with 7,12-dimethylbenz[a]anthracene followed by 12-O-tetradecanoylphorbol 13-acetate. *Cancer Sci* 95: 205-210, 2004.
22. Saranath D, Chang SE, Bhoite LT, Panchal RG, Kerr IB, Mehta AR, Johnson NW and Deo MG: High frequency mutation in codons 12 and 61 of H-ras oncogene in chewing tobacco-related human oral carcinoma in India. *Br J Cancer* 63: 573-578, 1991.
23. Suzui M, Yoshimi N, Tanaka T and Mori H: Infrequent Ha-ras mutations and absence of Ki-ras, N-ras and p53 mutations in 4-nitroquinoline 1-oxide-induced rat oral lesions. *Mol Carcinog* 14: 294-298, 1995.
24. Galiegue-Zouitina S, Bailleul B, Ginot YM, Perly B, Vigny P and Loucheux-Lefebvre MH: N2-guanyl and N6-adenyl arylation of chicken erythrocyte DNA by the ultimate carcinogen of 4-nitroquinoline 1-oxide. *Cancer Res* 46: 1858-1863, 1986.
25. Galiegue-Zouitina S, Bailleul B and Loucheux-Lefebvre MH: Adducts from in vivo action of the carcinogen 4-hydroxyaminoquinoline 1-oxide in rats and from in vitro reaction of 4-acetoxyaminoquinoline 1-oxide with DNA and polynucleotides. *Cancer Res* 45: 520-525, 1985.
26. Kohda K, Tada M, Hakura A, Kasai H and Kawazoe Y: Formation of 8-hydroxyguanine residues in DNA treated with 4-hydroxyaminoquinoline 1-oxide and its related compounds in the presence of seryl-AMP. *Biochem Biophys Res Commun* 149: 1141-1148, 1987.
27. Odajima T, Sasaki Y, Tanaka N, Kato-Mori Y, Asanuma H, Ikeda T, Satoh M, Hiratsuka H, Tokino T and Sawada N: Abnormal beta-catenin expression in oral cancer with no gene mutation: correlation with expression of cyclin D1 and epidermal growth factor receptor, Ki-67 labeling index, and clinicopathological features. *Hum Pathol* 36: 234-241, 2005.
28. Yoshida K, Tanaka T, Hirose Y, Yamaguchi F, Kohno H, Toida M, Hara A, Sugie S, Shibata T and Mori H: Dietary garcinol inhibits 4-nitroquinoline 1-oxide-induced tongue carcinogenesis in rats. *Cancer Lett* 221: 29-39, 2005.
29. Li N, Sood S, Wang S, Fang M, Wang P, Sun Z, Yang CS and Chen X: Overexpression of 5-lipoxygenase and cyclooxygenase 2 in hamster and human oral cancer and chemopreventive effects of zileuton and celecoxib. *Clin Cancer Res* 11: 2089-2096, 2005.
30. Pandey M, Prakash O, Santhi WS, Soumithran CS and Pillai RM: Overexpression of COX-2 gene in oral cancer is independent of stage of disease and degree of differentiation. *Int J Oral Maxillofac Surg* 37: 379-383, 2008.
31. Seo YR, Lee SH, Han SS and Ryu JC: Effect of p53 tumor suppressor on nucleotide excision repair in human colon carcinoma cells treated with 4-nitroquinoline 1-oxide. *Res Commun Mol Pathol Pharmacol* 104: 157-164, 1999.